

Joints in Scleroderma: Hydroxyapatite Disease

Rozin Alexander*, Daood Rula and Balbir-Gurman Alexandra

B. Shine Rheumatology Institute, Rambam Health Care Campus and Technion, Haifa, Israel

*Corresponding author: a_rozin@rambam.health.gov.il

Abstract. We report an inflammatory mechanism of joint damage in systemic sclerosis (SS) associated with hydroxyapatite (HA) deposits. This is an unusual asymptomatic case with an unusual localization of severe metatarsal–phalangeal joint disease. The patient had no hyperuricemia. We review the literature about HA deposit disease and discuss variable joint involvement in SS.

Keywords: Scleroderma, hydroxyapatite crystals, joints.

INTRODUCTION

The most common manifestations of articular involvement in systemic sclerosis (SS) are generalized arthralgia with mild pain and stiffness [1]. True joint inflammation, however, is possible [2, 3]. The onset might be sudden or gradual, and the pattern can be oligo- or polyarticular. All joints, excluding the fingers, may be involved. Wrists and ankles predominate, especially in patients with positive cyclic citrullinated peptide (anti-CCP) antibodies [4]. The joint symptoms tend to be intermittent or chronic remittent in nature. Aside from symptoms that may indicate the existence of early SS, clinical signs are frequently modest at the outset. Some individuals have localized joint discomfort or swelling, but joint effusions are less common and typically modest. Synovitis, erosions ($39 \pm 21\%$), and joint space narrowing ($43 \pm 25\%$) are all examples of joint damage [1, 5]. Tethering and rigidity of the underlying joints occur as the condition progresses, impairing mobility and function. An unnatural, permanent shortening of muscle or scar tissue is known as joint contracture. Observed in 31% of patients in the EUSTAR registry, it results in severe deformity [1].

PATIENTS AND METHODS

We would like to report another inflammatory mechanism of articular damage in scleroderma. HA deposits of soft tissues are observed in scleroderma individuals, who are prone to this condition. The reason for this phenomenon is probably ischemic tissue damage, which results in phosphate release connected to the soft tissue calcium. Diffuse

calcinosis of soft tissues may cause severe disability. We observed severe articular damage due to HA deposit. A 58-year-old woman is suffering from diffuse scleroderma with multiple organ involvement. An X-ray of both feet was performed because the ischemic toe IV left. The X-ray accidentally showed along with acro-osteolysis of the toes II–IV left severe bilateral metatarso-phalangeal (MTP) I joint damage with massive small round nonlinear radio-opaque peri- and intra-articular deposits compatible with calcium HA (Figure 1A). In this regard, computed tomography of the joint confirmed damage due to HA crystallopathy (Figure 1B). The patient had no any complaints related to MTP I disease. Inflammatory markers and white blood cells were normal. Physical examination data showed non-tender, thickened, immobile MTP I joints.

DISCUSSION

We previously reported bilateral stiff and painful glenohumeral joint disease in older men with severe HA crystal induced damage and massive synovial fluid with sparse mononuclear cytosis (Milwaukee shoulder) [6]. We were not pioneers in the field. Arthritis associated with apatite crystals was described 40 years ago [7–10]. Light microscopy may detect irregular clumps of apatite crystals in synovial fluid [11]. These clumps look like round or oval formations twice the size of neutrophils. The use of alizarin red S-staining as a screening test for calcium compounds in synovial fluid was investigated and proposed [12].

The very thin needles of 50–250 Å diameter may be identified using transmission electron microscopy or rod

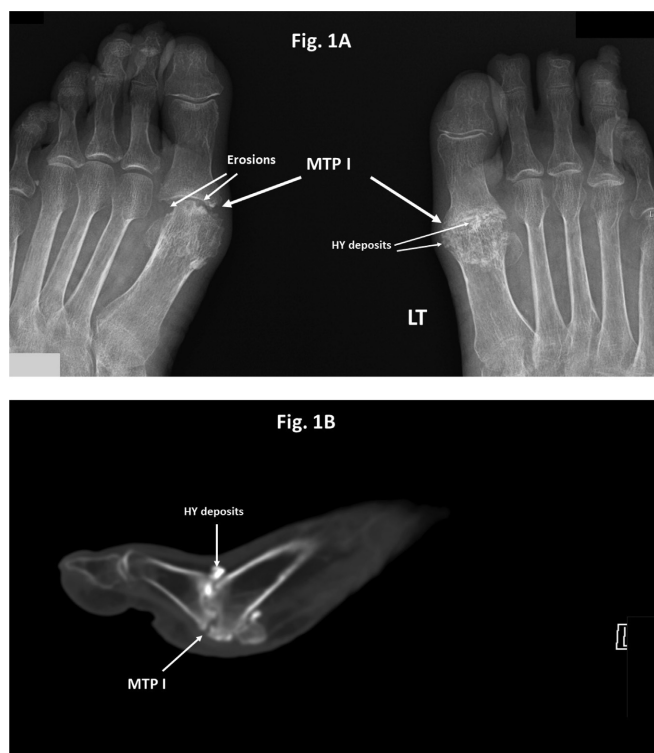


Figure 1. (A) The X-ray of both feet accidentally showed along with acro-osteolysis of the toes II–IV left severe bilateral metatarso-phalangeal (MTP I) joint damage with massive small round nonlinear radio-opaque peri- and intra-articular deposits compatible with calcium hydroxyapatite and the joint erosions. (B) A CT of the joint confirmed the joint damage due to HA crystallopathy.

and “boat-like” crystals (high magnification X125 000) within the characteristic apatite clusters. Another image to detect the apatite is the ferritin-conjugated antibody to IgG, displaying the binding of ferritin-labeled immune to clump [11].

Apatite and CPPD crystals were frequently detected in the same fluids. Positive staining was also seen in synovial fluids from individuals with osteoarthritis, renal failure, dialysis, rheumatoid arthritis, and gout. The association between positive alizarin red S-staining and radiologic evidence of osteoarthritis shows that apatite crystals may be linked to articular cartilage deterioration in various rheumatic illnesses [12].

CONCLUSION

Scleroderma, as one of the background diseases for HA joint deposits, was noted along with other autoim-

mune, endocrinal, and metabolic diseases [11]. But the isolated silent involvement of MTP I has not been previously reported. Hydroxyapatite Crystal Deposition Disease (HADD) is a well-known systemic illness with an unclear origin, characterized by para-articular and/or intra-articular HA crystal deposition. Although not all patients experience symptoms, the condition is clinically manifested by localized pain, edema, and tenderness around the affected joint, as well as varying limitations in joint mobility [13]. HA-induced damage in scleroderma may be severe and asymptomatic.

REFERENCES

- [1] Avouac, J., Clements, P.J., Khanna, D., et al. (2012). Articular involvement in systemic sclerosis. *Rheumatology*. 51, 1347–1356.
- [2] La Montagna, G., Baruffo, A., Tirri, R., et al. (2002). Foot involvement in systemic sclerosis: a longitudinal study of 100 patients. *Semin Arthritis Rheum*. 31, 248–255.
- [3] La Montagna, G., Sodano, A., Capurro, V., et al. (2005) The arthropathy of systemic sclerosis: a 12 month prospective clinical and imaging study. *Skeletal Radiol*. 34, 35–41.
- [4] Morita, Y., Muro, Y., Sugiura, K., et al. (2008) Anti-cyclic citrullinated peptide antibody in systemic sclerosis. *Clin Exp Rheumatol*. 26, 542–547.
- [5] Avouac, J., Guerini, H., Wipff, J., et al. (2006) Radiological hand involvement in systemic sclerosis. *Ann Rheum Dis*. (2006). 65, 1088–1092.
- [6] Rozin, A.P., Toledano, K., Balbir-Gurman, A., et al. (2012) The Dancing Hare (Milwaukee Hematoma). *J Rheumatol*. 39, 2361.
- [7] Dieppe, P.A., Crocker, P., Huskisson, E.C., et al. (1976) Apatite deposition disease. A new arthropathy. *Lancet*. 1976 I, 266–269.
- [8] Schumacher, H.R., Somlvo, A.P., Tse, R. L., et al. (1977). Arthritis associated with apatite crystals. *An Intern Med*. 87, 411–416.
- [9] Schumacher, H.R., Miller, J.L., Ludivico, C., et al. (1981). Erosive arthritis associated with apatite crystal deposition. *Arthritis Rheum* 24, 31–37.
- [10] Schumacher, H.R., Miller, J.L., Ludivico, C., et al. (1981). Erosive arthritis associated with apatite crystal deposition. *Arthritis Rheum*. 24, 31–37.
- [11] Schumacher, H.R., Cherian, P.V., Reginato, A.J., et al. (1983). Intra-articular apatite crystal deposition. *Ann Rheum Dis*. 42, Suppl: 54–59.
- [12] Paul, H., Reginato, A.J., Schumacher, H.R. (1983). Alizarin red S-staining as a screening test to detect calcium compounds in synovial fluid. *Arthritis Rheum*. 26(2), 191–200.
- [13] Garcia, G.M., McCord, G.C., Kumar, R. (2003). Hydroxyapatite crystal deposition disease. *Semin Musculoskelet Radiology*. 7(3), 187–193.